



ENDOSCOPIC TRANSFORAMINAL LUMBAR DISCECTOMY AND RECONFIGURATION: A POSTERO-LATERAL APPROACH INTO THE SPINAL CANAL

David A. Ditsworth, M.D.

Division of Neurosurgery, Cedars-Sinai Medical Center, Los Angeles, California

Ditsworth DA. Endoscopic transformaminal lumbar discectomy and reconfiguration: a postero-lateral approach into the spinal canal. *Surg Neurol* 1998;49:588-98.

BACKGROUND

In the past, minimally invasive procedures (chemonucleolysis, laser, automated percutaneous discectomy, percutaneous manual nucleotomy, arthroscopy) have been largely confined to intradiscal work. This study represents cases of working channel, transforaminal spinal endoscopy performed using an endoscope which, because of its small size and flexibility, can bend up to 90 degrees (depending on the guiding cannula), and pass completely through the foramen into the spinal canal (truly transforaminal, as opposed to just going through part of the foramen and into the disc), to directly remove free fragments and reconfigure disc, relieving root and dural displacement at all lumbar levels.

METHODS

The records of 533 patients who had outpatient, minimally invasive operations performed over a 6-year period (ending in 1995) by this author were analyzed. Of these, 110 had small scope transforaminal procedures, forming the basis of this study.

RESULTS

An independent observer followed the 110 patients who had endoscopic transforaminal procedures for 2 or more years. Using MacNab's criteria, the success rate (excellent or good) was 95% in the 75 patients with disc presenting lateral to the dura—"lateral presenting,"—and 83% in the 35 patients not presenting disc for direct removal—"non-lateral presenting" (i.e., dura in the pathway)—making an overall success rate of 91%. One patient who developed discitis was the only complication.

CONCLUSION

Guideable endoscopes small enough to pass completely through the foramen allow percutaneous surgery to include non-contained disc herniations and even some mi-

grated free fragments, depending on the location. The percutaneous transforaminal endoscopic technique can be an effective, safe approach for disc removal through the foramen, especially in cases where the disc presents itself for direct removal. © 1998 by Elsevier Science Inc.

KEY WORDS

Endoscopy; surgery; minimally invasive; discectomy, percutaneous; lumbar vertebrae; anesthesia, local; foramen; transforaminal.

INTRODUCTION

Whereas endoscopic techniques used in other areas of the body have become commonplace, spinal endoscopic techniques have developed more slowly. This is because of the complex anatomy and difficult access, and the lack of equipment designed specifically for spinal endoscopy. In the spine, working space is confined deep within the body, with access to pathology hampered by the bony structures and the presence of soft tissue, epidural vessels, nerve roots, and dura.

The history of open surgical treatment of herniated lumbar discs started with Mixter and Barr [22] and Dandy [4], over 60 years ago. Williams described microlumbar discectomy in 1978 [31]. This is a small incision technique using an external overhead microscope. It is, of course, a small open operation that requires a posterior midline skin incision of at least 1 inch (for one level), incision of paravertebral fascia, detachment of muscle, removal of a portion of the ligamentum flavum, usually bone removal, retraction of the root and dural sac, and opening of the disc inside the spinal canal.

Minimally invasive endoscopic methods, performed by passing the scope from the skin surface,

Address correspondence and reprint requests to: Dr. David A. Ditsworth, Division of Neurosurgery, 1125 South Beverly Drive, Suite 425, Los Angeles, CA 90035.

Received March 28, 1997; accepted November 17, 1997.

should be differentiated from open surgery. These are puncture opening (percutaneous) procedures, with skin openings just large enough to admit the scope, for internal viewing through scope placement directly at the tissue to be addressed, as compared with working from an external view, either with or without a microscope, through an open incision.

The evolution of these percutaneous methods to the current state-of-the-art can be traced with an historical overview of the basic approaches: chemonucleolysis [15], laser [5], manual, and automated percutaneous lumbar discectomy [21, 24, 25, 27], and arthroscopy [17]. In 1948, Valls, et al [30], and in 1956, Craig [3], described the posterior lateral approach for bone biopsy. Lyman Smith first used Chymopapain to treat a lumbar disc disorder in 1964 [29]. The posterolateral extradural route to the lumbar disc was described by Day in 1969 [6]. Percutaneous nucleotomy was developed by Hijikata in 1975 [12-14]; Kambin, in 1983 [17] and thereafter, described arthroscopic techniques and equipment for posterior and posterolateral herniated disc removal, via intradiscal access [18]. Then in 1985, Onik [24] developed the nucleotome for automated percutaneous lumbar discectomy. In 1987, Choy reported using a laser to treat herniated lumbar discs [1]. Subsequently, in 1993, percutaneous endoscopic discectomy with a medium-size, straight, rigid endoscope at L4-5 and above was described by Mayer and Brock [21] in a prospective, randomized series of cases, using manual and automated tools; they reported 95% of endoscopic patients returning to their previous occupations, compared with 72% in their open microdiscectomy group. More recently, Kambin and others have described larger scope "foraminal access" approaches [19], but because straight scopes will not go around corners and large scopes will not pass into small openings, these efforts have been limited to working inside the foramen, or perhaps reaching tools through the foramen, without the advantage of having the entire scope go through in such a way that the scope itself is directly on the herniation.

The small, guided endoscopic, completely transforaminal technique (the subject of this paper) was described in detail at the AANS meeting in April, 1996 [8], and was commended by Dr. Dunsker, an official of the AANS, as "the surgery of the future." [9] (personal comm.)

MATERIALS AND METHODS





The records of 533 patients who had outpatient percutaneous discectomies (endoscopic and non-

endoscopic, using a wide range of equipment and techniques) performed during a 6-year period under local anesthesia and IV sedation by this author were analyzed. The equipment and techniques for performing completely transforaminal endoscopic discectomies did not exist initially, and were developed over time, eventually enabling 110 patients to have small scope, endoscopic, completely transforaminal procedures with the equipment shown (Figure 1), forming the basis of this study. Patients having only a partial foraminal approach are not included in the 110 cases. These 110 patients were not pre-selected, as the criteria for ideal candidates (described below) only gradually became apparent.

The 110 patients (70 males and 40 females) ranged in age as follows: 47 patients, 20-40 years; 52 patients, 40-60 years; and 11 patients, over 60 years. These 110 patients presented the following symptoms and physical findings: all patients had back pain, and all patients had sciatica. Ninety-five percent had limitation of forward bending. Ninety-four percent had positive Lasegue's sign. Seventy-eight percent had sensory loss. Thirty-five percent had motor loss. Forty percent had reflex changes. The average duration of sciatica was 5 months. The average duration of supervised trial of conservative management pre-operatively (including physical therapy) was 3 months.

Of the 110 cases, the following disc levels were endoscopically treated: 52% involved L4-5, 41% L5-S1, and 7% higher lumbar levels. Of these 110 cases, 75 had either a laterally presenting or a foraminal disc herniation. The other 35 were either central herniations or postero-lateral, but did not present for direct endoscopic access (the endoscope itself could not be placed directly into the actual herniation). Of these 110 cases, 66 had noncontained disc material, and 44 had contained disc herniations. A specimen of pathologic disc was sent to pathology in all cases. Sixty-four of these sixty-six extruded disc cases presented disc material for direct removal. The 66 noncontained disc material cases were determined by analysis of magnetic resonance imaging (MRI) computed tomography (CT), and discography (in some cases, CT-discography) results, as well as the endoscopic observations themselves.

These 110 cases represent cases of working-channel transforaminal spinal endoscopy performed with an endoscope consisting of a plastic scope that can bend to any angle up to 90 degrees or more, depending on the guiding cannula, passing through the foramen to remove free fragments and reconfigure disc, relieving root and dural displacement (Figure 1). Access is obtainable to the lateral



1 (A) Demonstrates transforaminal endoscopic approach at L5-S1 on a human spine (grasper is extending beyond the plastic scope, which extends beyond the mildly curved outer metal cannula. All are readily passing completely through the foramen into the spinal canal). Actual surgical position will vary, depending on access anatomy and location of pathology. (B) Coupler, cannula, camera, cannulas, tools, working channel scope (white), viewing scopes (black). (C) Flexibility of working channel scope. (D) Cannulas: straight, standard curved, 40-degree curved. (E) Tools that pass through the scope: hook, ball, curette, dissector, and grasper.

recess and other locations within the spinal canal usually thought only reachable with open surgery. This author developed the percutaneous working-channel scope technology, which includes the various working-channel and viewing scopes, along with tools and cannulas for use with them, for percutaneous spinal endoscopy. The scope, designed

specifically for passing completely through the foramen, is a 2.8-mm bendable plastic tube with fiber-optics in the wall (Figure 1), providing 6000 or 12,000 pixel resolution, with a separate viewing scope for high resolution viewing only (not working-channel), which alternates with the working channel scope in passing down the 4.2-mm O.D.

outer metal cannula. There are a series of directing, outer metal cannulas with varying degrees of curvature. Tools for use through the working channel include a curette, ball dissector, No. 4 Penfield shaped dissector, suction, blunt probe, hook, grasper (alligator and cup tip), and nucleotome.

INDICATIONS FOR TRANSFORAMINAL ENDOSCOPIC DISCECTOMY

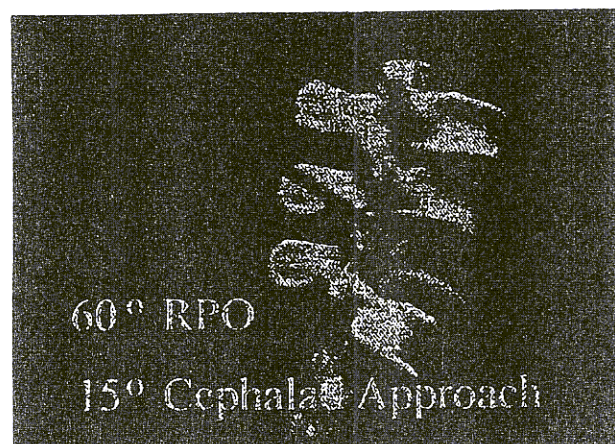
Whereas the criteria for percutaneous nucleotomy have been described in numerous papers and require that the disc be contained, the criteria for the endoscopic transforaminal approach (this approach, of course, includes a nucleotomy with the technique described here) incorporate these previous criteria, and expand the criteria to include non-contained herniations and even free fragments. Contained herniations treated with this two-pronged approach (see Figure 4) can be pushed back and reconfigured externally as well as internally decompressed. When pathologic disc compression is treated, there is visual confirmation.

This technique is ideally suited for unilateral, one-level extruded discs and free fragments; most preferably, free fragments in the spinal canal that are readily accessible to the foramen and soft and compressible enough to be delivered as one piece or piecemeal through a small scope.

1) There is persistent radicular pain, numbness, or weakness, caused by disc herniation compromising root or roots (contained or, preferably, non-contained) confirmed by CT, MRI, myelogram, or discogram (study correlating with clinical status); 2) positive tension or compression signs, or motor, sensory or reflex abnormalities are present; 3) the patient is not responding to conservative treatment; 4) this technique is optimal with extruded discs and free fragments; or 5) the patient is obese or in poor health so that open surgery would be an increased risk. (This is an additional consideration.)

CONTRA-INDICATIONS

Possible contra-indications include: 1) Spinal stenosis including lateral lumbar spinal canal stenosis, unless root compromise by disc is a significant component; 2) bony spurs, facet hypertrophy, or ligamentous hypertrophy are causing neurologic symptoms; 3) there is significant spinal instability; 4) the free fragment or fragments to be removed are inaccessible; 5) the herniated disc is calcified or



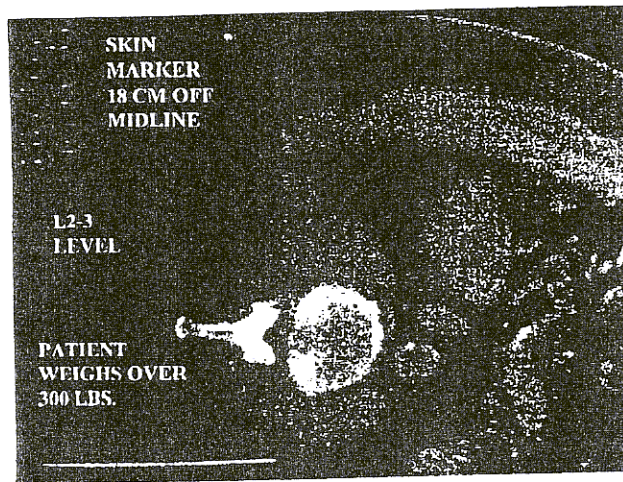
2 Sixty degree RPO shows pointer coming into the triangular zone.

very hard; 6) significant cicatrix or arachnoiditis is causing the patient's symptoms; and 7) the access pathway through the foramen, as seen on the pre-operative studies, seems inadequate.

TECHNIQUE

In 1983, the posterior-lateral approach through the "triangular working zone" was described by Kambin [17]. Its anterior boundary is the spinal nerve; inferior boundary, the proximal plate of the lower lumbar segment; and posterior boundary, the proximal articular process of the inferior vertebra (Figure 2). The Kambin technique for "transforaminal arthroscopic decompression of lateral recess stenosis" has been described as using a 6.4-mm OD straight access cannula for "foraminal decompression," which "does not require entry into the spinal canal [16]." This seems to be a good approach for taking down "fibrotic and calcified annular fibers and small osteophytes," which are accessible inside the foramen using the larger cannula and scope [16]. However, in this approach, the scope is not passed completely through the foramen into the spinal canal.

The small-scope technique, passing the scope completely through the foramen into the spinal canal (described below) differs from the above and is currently not usable to remove osteophytes or calcified tissue. This technique is best suited for extruded discs and free fragments in the spinal canal that are accessible to the foramen. Even the L5-S1 level is usually treatable, because of the guiding cannula's curvature and small size and the unique ability to readily pass the scope, and even the cannula, completely through the foramen.



3 CT in the lateral position, with the symptomatic side up; surface marker to guide placement.

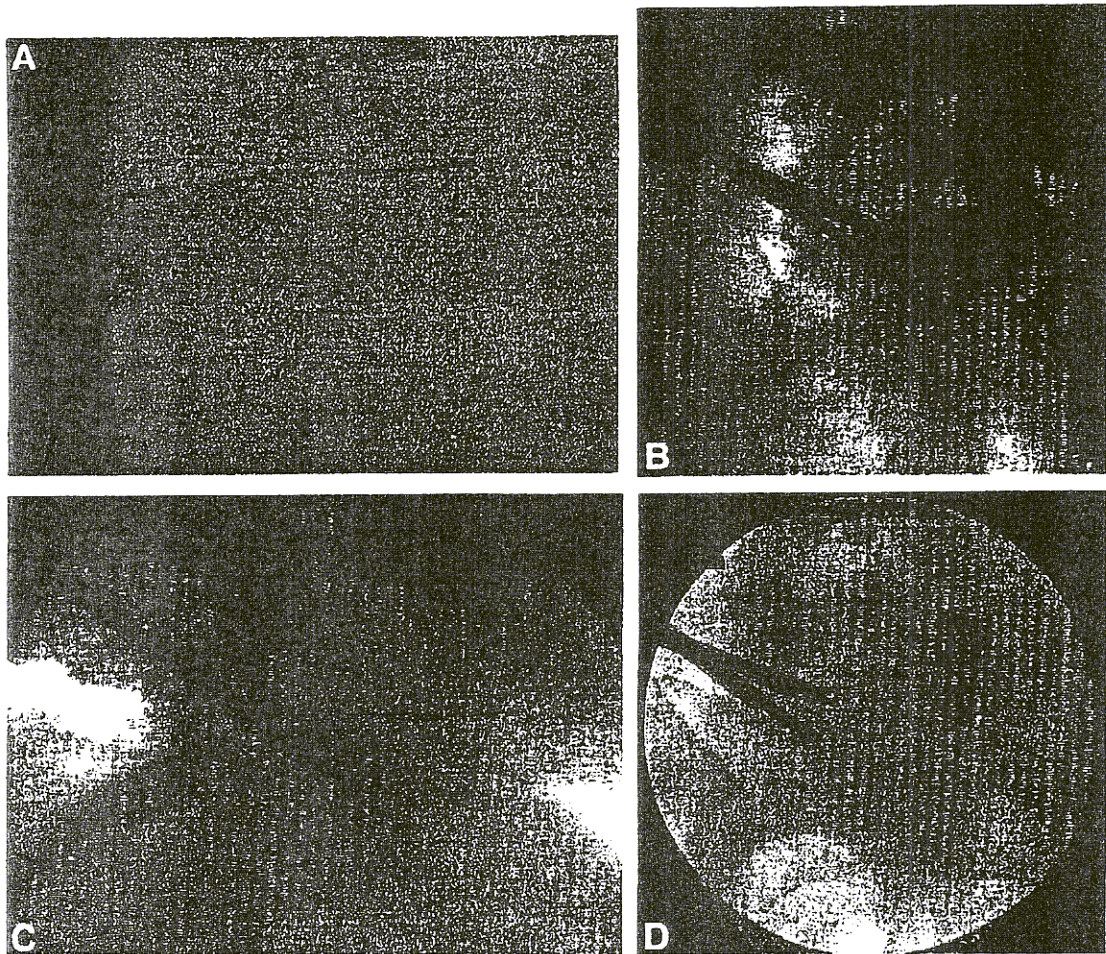
An important step prior to surgery is a wide view CT scan for access analysis (Figure 3). The patient is placed in the scanner in the lateral decubitus position with the symptomatic side up, for slices through the affected level with a surface marker, 12-cm off midline (farther if in a very obese patient). In this position, the ipsilateral abdominal structures will fall forward somewhat. This demonstration of the surgical access pathway allows precise planning with the greatest margin of safety.

The full transforaminal technique, going completely through the foramen into the spinal canal, involves two steps (performed during one operation). First, a standard partial nucleotomy is done; then, the completely transforaminal portion is performed as a second step. The surgery is performed in the operating room, generally in the lateral decubitus position, with AP and lateral fluoroscopy. A prophylactic antibiotic is given before surgery. Using local anesthetic and IV sedation, a skin opening 5 mm in length is made at a point ranging from 8 cm to 22 cm lateral to the midline (determined by the pre-operative CT scan and marker; greater distance in obese patients (Figure 3); taking care to chart a safe course behind abdominal structures) and above the iliac crest. Through this opening, the guidewire and a 4.2-mm OD metal cannula are placed, providing access to the region. An opening is made in the annulus, coming through the working zone, and nucleus is removed under endoscopic vision, either with a grasper, curette, suction, laser, or nucleotome. The precisely desired point of entry into the nucleus and the exact path through the disc can usually be selected and obtained by careful correlation with plain films and the CT scan. The

nucleotomy is done as directly under the herniation as possible and provides internal decompression, allowing simultaneous transforaminal reconfiguration and displacement of disc into this decompression (Figure 4). Also, the annulotomy opening provides a decompression site away from the herniation, decreasing the likelihood of recurrent herniation. After the nucleotomy, the second portion of the operation is the truly transforaminal part, going completely through the foramen and into the spinal canal. This is frequently accomplished with a curved cannula, which is inserted down over the place-holding guidewire to the annulotomy site, working the curved cannula and scope through the foramen. At times it is necessary to make a separate opening further lateral from the first opening on the skin surface to get a straighter shot through the foramen (Figure 4). Sometimes straight cannulas and straight scopes can be placed completely through the foramen; at other times curved cannulas are needed. Because the bendable fiberoptic system passing through curved cannulas is currently for one-time use only, and the straight cannula system is reusable, the cost savings per patient is significant for the latter. The transforaminal part of the operation typically adds approximately 30 min to the procedure.

The 2.8-mm plastic bendable working-channel endoscope is then placed down through a cannula (after selecting the optimal cannula curvature) past the triangular working zone, through the foramen. Down this working channel, the grasper and other instruments described above are then used to remove or reconfigure the herniated disc in lateral presenting cases (i.e., at least a portion of the protruding, extruded, or free-fragmented disc material is accessible to the transforaminal approach directly) (Figures 5 and 6). Working on the surface of the annulus and viewing with the endoscope, the annulus can be milked with the cannula or a blunt probe, and if the disc is soft, it will pop out through the hole in the annulus for easy removal. This also provides reconfiguration and reshaping of the annulus, just as is done in open surgery by applying external pressure to the wall of the disc.

The transforaminal technique in non-lateral presenting cases (i.e., dura in the pathway) consists of making an access point near the dura at such an angle that the disc removal is directly under the disc herniation. The accessible annulus is also milked and reconfigured as described above. Sometimes rounded tools are slipped under the dura to reshape the disc.





4 (A) Skin marking, showing puncture opening 12 cm off midline for nucleotome, and 22 cm off midline for working channel scope and grasper. [X] shows position of foramen as found on lateral fluoroscopy. (B) AP view of transforaminal position of grasper (passed from 22 cm off midline skin opening); shown in comparison to nucleotomy position of nucleotome (passed from 12 cm off midline skin opening). (C) Lateral view of transforaminal position of grasper (passed from 22 cm off midline skin opening); shown in comparison to nucleotomy position of nucleotome (passed from 12 cm off midline skin opening). (D) AP view of transforaminal position of grasper (passed from 18 cm off midline skin opening); shown in comparison to nucleotomy position of nucleotome (passed from 10 cm off midline skin opening). (E) Lateral view of transforaminal position of grasper (passed from 18 cm off midline skin opening); shown in comparison to nucleotomy position of nucleotome (passed from 10 cm off midline skin opening).

FOLLOW-UP

The author initially evaluated all patients 6 weeks after the procedure. Subsequently, all patients were followed up over the course of 2-4 years. This was done by physical examination by the

author and concomitant questionnaire; or, in the case of those patients who did not return, by telephone interview and questionnaire. An independent neuropsychologist (R.A.G., Ph.D.) reviewed all the questionnaires and also conducted the telephone interviews.



5 (A) Thirty-six-year-old with a laterally presenting free fragment at L4-5 (T1 weighted axial view just below disc level). (B) T2 weighted sagittal image. (C) Shows this fragment on the specimen table, two centimeters long (this was the largest of the 110 cases).

Very few of the patients (approximately 5%) in this series had Workers' Compensation cases.

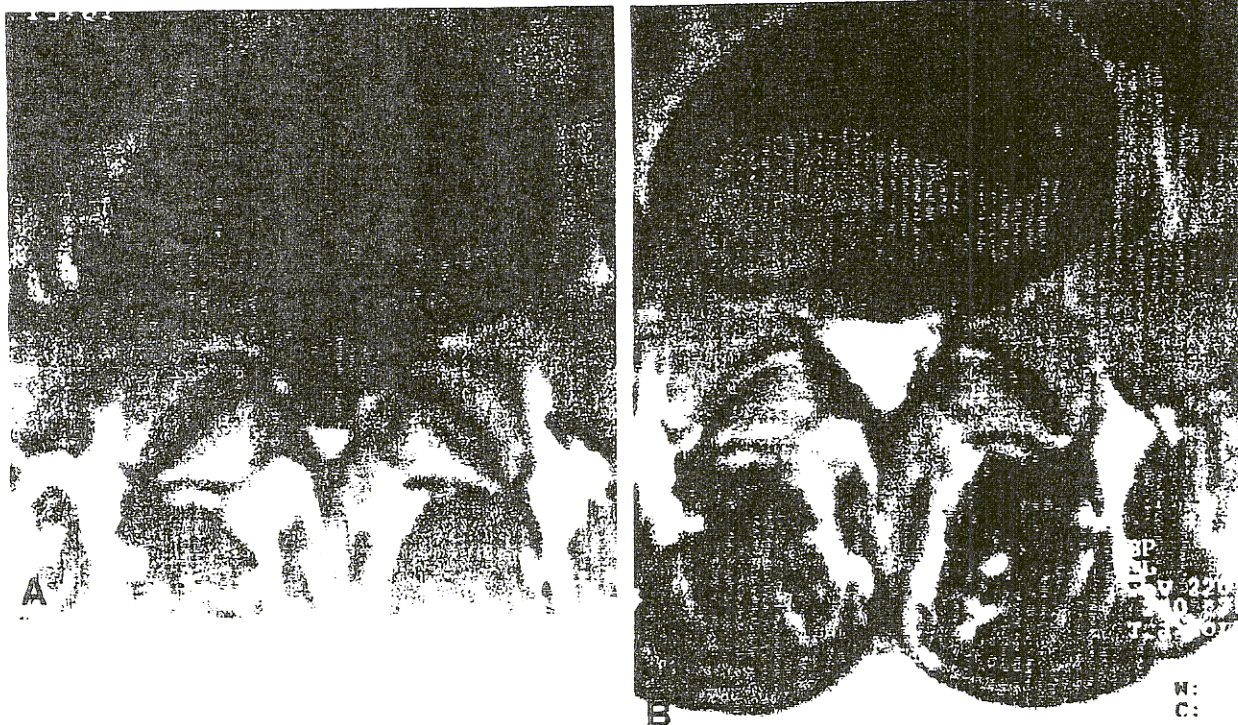
RESULTS

Of the 110 patients, 63 had excellent results, 37 had good results, 5 had fair results, and 5 had poor results, according to the MacNab criteria [20] (Excellent = no pain, no restriction of activity; Good = occasional back or leg pain of sufficient severity to interfere with the ability to do normal work or capacity to enjoy leisure hours; Fair = handicapped by intermittent pain of sufficient severity to curtail or modify work or leisure activities, but improved functional capacity; and Poor = no improvement or insufficient improvement to enable increase in activities; further operative intervention required), with an overall success rate of 91%. The only complication was one case of bacterial discitis, which resolved with antibiotics.

Of the five poor results, all underwent laminectomy/laminotomy subsequently. Two patients had a laminectomy performed by outside surgeons. The other three patients had microdiscectomies performed by this author. The failures were due to: A) a free fragment having migrated too far and too centrally in the canal to be effectively removed endoscopically (two patients, 51 and 53 years of age), B) a central, calcified disc (one patient, 35 years of age), C) bony osteophytes that had to be taken down at open surgery (one patient, 47 years of age), and D) a previous laminectomy with residual epidural scarring. This patient had a contained herniation, causing foot drop, that was treated endoscopically with insufficient response; therefore, open microdiscectomy was done and symptoms gradually improved (one patient, 34 years of age).

Five patients had had prior lumbar laminectomies at the same location (same level and side). In this group, three were successful (two excellent, one good) and two were failures (one poor and one fair). Because the success rate in this group was only three out of five (60%), it seems that the prognosis for this group is worse than the virgin group. However, the primary factors seem to be the nature and location of the pathology (extrusion, free fragment, contained herniation, etc.) and the anatomic accessibility. The history of previous surgery is only one factor to be considered, not a contraindication.

The overall success rate for the 75 lateral presenting or foraminal cases was 95%, and 83% for the 35 nonlateral presenting. The overall success rate



6 (A) MRI, pre-operative, of a 45-year-old male with an 11-mm extruded L5-S1 fragment. (B) MRI, 5 weeks postoperative endoscopic transforaminal discectomy, shows that the fragment has been removed.

of the 110 patients was 91% (excellent or good results are considered successful).

DISCUSSION

ANATOMIC CONSIDERATIONS

It has been noted that the nerve root ganglia, which are known to be quite sensitive to mechanical distortion, usually lie directly beneath the pedicle in the foramen [2]. Compression of the ganglia causes disproportionately prolonged electrical activity. As the laterally presenting disc is common, the effect caused by the herniated disc on the ganglia is therefore a matter for frequent consideration. The ganglion can usually be directly decompressed endoscopically using the transforaminal approach.

Radicular venous stasis caused by compression of venous connections by the laterally presenting disc herniation affecting the inferior part of the foramen seems to be a factor in sciatica, and can also be treated with percutaneous endoscopic surgery [26].

ADVANTAGES OF THE SMALL ENDOSCOPIC TRANSFORAMINAL APPROACH

Percutaneous endoscopic spinal surgery uses the same, inherently safe pathway to the disc that is

used in percutaneous nucleotomy, the posterolateral approach. This path is well-established and offers a starting point for transforaminal procedures using the natural portal of the foramen to reach the spinal canal.

The basic access route for the typical percutaneous nucleotomy, not full transforaminal, with radiological confirmation of working location inside the disc, has been said to be extremely safe [11] and shown to be atraumatic with postoperative studies [28]. The complication rate of percutaneous nucleotomy is low 1% [25] and the complications are generally not severe: psoas hematoma [10], vasovagal, postoperative spasm, and discitis [7,14,23].

Fluoroscopic guidance confirms the correct level and allows the endoscope to be placed right at the herniation by correlating with the preoperative films. Of the 533 percutaneous discectomies performed by this author over a 6-year period, there was no incidence of operating upon the wrong level.

Endoscopic tools can be observed when in use, and the surgeon can look around a corner or down a small hole. Adding the visualization of an endoscope and moving outside the disc increases the effectiveness and range of application and can also be safely done. As stated previously, in the present series of 110 endoscopic cases, the only complication was one case of bacterial discitis. In the entire

series of 533 cases, there have not been any cases of misplaced instruments, instruments broken off inside the patient, torn dura, injured or transected nerve roots, or significant hemorrhage. Minimal recovery time: in this study, patients left the hospital 3 h after the procedure, on average, with most patients returning to work within 3 days.

DISADVANTAGES OF THE PERCUTANEOUS ENDOSCOPIC TRANSFORAMINAL TECHNIQUE

The disadvantages of this technique include the following: 1) There is limited ability to work around pathology. The surgeon cannot dissect freely in the canal; 2) It may only be possible to remove part of the extruded disc (although in most cases a partial removal is sufficient); 3) harder tissue can not be removed very well with a small endoscope; 4) the completely transforaminal approach with the current equipment (Figure 1) seems to be less beneficial if the pathology is not directly accessible when coming through the foramen, and seems to have a lower success rate (83% success in the 35 cases in this series).

COMPARISON OF VARIOUS PERCUTANEOUS APPROACHES

The surgeon must consider the size of tools for percutaneous spine surgery; small cannulas and tools are relatively atraumatic and are well tolerated by patients. The ability to place the small scope itself and even the cannula completely through the foramen at L5-S1 particularly is a capability unique to equipment of this size and configuration. Visualizing the tissue at the open end of the working channel scope while using the various tools to dissect and remove the herniated disc is key to success and safety. The endoscope is essential for transforaminal extradiscal work, and although not essential for intradiscal work, is helpful and reassuring. The various tissues—disc of various consistencies, cartilage, bone, ligament, muscle, fat, vessel, nerve, and dura—are readily identifiable under the endoscope. The endoscope allows the surgeon to be certain of the tissue being dealt with, and if a problem should arise, such as bleeding, it can be visualized and treated.

Percutaneous endoscopic spine surgery is a newly emerging field. One of the primary challenges is the matching of the particular pathology and anatomy in the specific patient to the available techniques, instrumentation, training, and experience of the surgeon. Obviously, if the surgeon wishes to treat a range of disorders, then a range of approaches and equipment need to be available.

The small scope endoscopic techniques are easier to learn than the use of larger scopes. This is because the basic small nucleotomy approach has been widely taught, and small scopes are less traumatic in a small space. To advance from that basic, small nucleotomy technique to include manual, small endoscope work is not such a big step for surgeons already trained in the basic approach.

The author thanks Dr. Patrice Tumin Tarsey, and Rupert T. Ditsworth, for their invaluable assistance in the preparation of this manuscript and Dr. Robert Arthur Gallway for interviewing the patients and reviewing the questionnaires.

REFERENCES

1. Choy DSJ, Altman P. Fall of intradiscal pressure with laser ablation. *Spine State Art Rev* 1987;7:23-9.
2. Cohen MS, Wall EJ, Brown RA, Rydevik B, Garfin SR. Cauda equina anatomy II: extrathecal nerve roots and dorsal root ganglia. *Spine* 1990;15:1248-51.
3. Craig FS. Vertebral biopsy. *J Bone Joint Surg* 1956;38A:93-102.
4. Dandy WE. Loose cartilage from intervertebral disc simulating tumor of the spinal cord. *Arch Surg* 1929;19:660.
5. Davis JK. Percutaneous laser discectomy. In: Cohen AR, Haines SJ, eds. *Minimally invasive techniques in neurosurgery; concepts in neurosurgery, Volume 7.* Williams & Wilkins, 1995:254-7.
6. Day PL. Lateral approach for lumbar diskogram and chemonucleolysis. *Clin Orthop* 1969;67:90-3.
7. Ditsworth DA, Robson D. Endoscopic evaluation of aseptic spondylodiscitis. Presented at the annual meeting of the Joint Section on Disorders of the Spine and Peripheral Nerves (CNS/AANS), Lake Buena Vista, Florida, 1996.
8. Ditsworth, DA. AANS annual meeting. Invited Speaker, "Spinal Endoscopy," April, 1996.
9. Dunsker S. Personal communication, 1996.
10. Gill K. Retroperitoneal bleeding after automated percutaneous lumbar discectomy—a case report. *Spine* 1990;15.
11. Gill K, Blumenthal SL. Automated percutaneous discectomy—long-term clinical experience with the nucleotome system. *Acta Orthop Scand* 64(Suppl 251):30-33, 1993.
12. Hijikata SA. A method of percutaneous nuclear extraction. *J Toden Hosp* 1975;5:39.
13. Hijikata S, Yamagishi M, Nakayama T, Oomori K. Percutaneous discectomy: a new treatment method for lumbar disc herniation. *J Tokyo Denryoku Hosp* 1975;5:39.
14. Hijikata S. Percutaneous nucleotomy—a new concept technique and 12 years experience. *Clin Orthop* 1989;238:9-23.
15. Javid MJ. Chemonucleolysis. In: Cohen AR, Haines SJ, eds. *Minimally invasive techniques in neurosurgery; concepts in neurosurgery, Volume 7.* Baltimore: Williams & Wilkins, 1995:240-6.
16. Kambin P, Casey K, O'Brien E, Zhon C. Transforaminal arthroscopic decompression of lateral recess stenosis. *J Neurosurg* 1996;84:462-7.

17. Kambin P, Gellman H. Percutaneous lateral discectomy of the lumbar spine: a preliminary report. *Clin Orthop* 1983;174:127.
18. Kambin P. Arthroscopic microdiscectomy. *Arthroscopy* 1992;8:287-95.
19. Kambin P, Zhou L. History and current status of percutaneous arthroscopic disc surgery. *Spine* 1996;245:575-615.
20. MacNab I. Negative disc exploration. *J Bone Joint Surg* 1971;53A:891.
21. Mayer HM, Brock M. Percutaneous endoscopic discectomy: Surgical technique and preliminary results compared to microsurgical discectomy. *J Neurosurg* 1993;78:216-25.
22. Mixter W, Barr J. Rupture of intervertebral disc with involvement of the spinal canal. *N Engl J Med* 1934;211:210-5.
23. Monteiro A, Lefevre R, Pieters G, Wilmet F. Lateral decompression of a pathological disc in the treatment of lumbar pain and sciatica. *Clin Orthop* 1989;238:56-63.
24. Onik G, Helms C, Ginsberg L, Hoaglund F, Morris J. Percutaneous lumbar discectomy using a new aspiration probe. *AJNR* 1985;6:290.
25. Onik, et al. Automated percutaneous discectomy: prospective multi-institutional study. *Neurosurg* 1990;26:228-33.
26. Parke WW. Anatomy of the spinal nerve and its surrounding structures. *Sem Orthoped* 1991;(2):65.
27. Quigley MR, Maroon JC. Automated percutaneous discectomy. In: Cohen AR, Haines SJ, eds. *Minimally invasive techniques in neurosurgery*. Baltimore: Williams & Wilkins, 1995:247-53.
28. Romy M. Review of 356 consecutive percutaneous discectomies with lumbar CT-scans done within five hours after the procedure. Presented at the annual meeting of the International Intradiscal Therapy Society, La Jolla, California, 1995.
29. Smith L. Enzyme dissolution of the nucleus pulposus in humans. *JAMA* 1964;187:137-40.
30. Valls J, Ottolenghi EC, Schajowicz P. Aspiration biopsy in diagnosis of lesions of vertebral bodies. *JAMA* 1948;136:376.
31. Williams R. Microlumbar discectomy—a conservative surgical approach to the virgin herniated lumbar disc. *Spine* 1978;3-2:175-82.

COMMENTARY

The author has summarized his experience with endoscopic transforaminal lumbar discectomy in 110 patients and reports the remarkably high success rate of 95% excellent to good results with his technique. The author also well summarizes the disadvantages of the percutaneous endoscopic technique, which are as follows: the limited ability to work around the pathology; the fact that it may only be possible to remove part of the extruded disc, and that osteophytes cannot be removed; and the fact that the transforaminal approach seems to add little if the pathology is not directly accessible when coming through the foramen.

In addition, I would add that the learning curve

for this technique would be quite steep for those unfamiliar with percutaneous techniques. That does not mean that new techniques and instrumentation should not be vigorously pursued and reviewed in a critical fashion, but in my opinion, such extraordinary results would be difficult to duplicate.

Joseph C. Maroon, M.D.
Division of Neurosurgery
Allegheny General Hospital
Pittsburgh, Pennsylvania

Dr. Ditsworth is certainly to be congratulated on his contribution to the technical design and surgical engineering of small size transforaminal spinal endoscopes. The technology provides an additional pathway to the lumbar lateral recess and has proved successful for him as a surgical alternative for the treatment of unilateral, single-level, laterally presenting herniated lumbar discs and extruded fragments. He is to be commended for this achievement. This type of nerve root compressive pathology, in such pure form, occurred in approximately 15% of my lumbar surgical cases over a 25-year period. These patients were an absolute joy to care for.

The transforaminal instrumentation would appear to provide more confidence in the removal of extruded disc fragments approximating a foramen than for the adequate decompression of an associated disc herniation. For this reason, Dr. Ditsworth precedes transforaminal endoscopy with percutaneous nucleotomy/discectomy. This combined surgical approach with initial internal disc decompression followed by further transforaminal disc decompression and removal of extruded fragments apparently is necessary to achieve a "91% surgical success." This suggests to me that neither technique in itself provides the means for a consistent successful surgical resolution in this highly selective but most desirable type of patient.

Additionally, in this day and age of attempted cost containment, the necessity for dual percutaneous surgical procedures, each with its specialized operating room equipment and radiology support, might prove to be extremely expensive for the health care payee. After all, the condition receiving treatment should be the simplest of all spinal surgery problems to resolve. Although his postsurgical patients are not hospitalized overnight, providing some cost savings, a 3-day return to work could prove to be the real economic miracle! From my experience, however, patients with weightbearing and car-riding occupations might find this very dif-

difficult to achieve. Unfortunately, 35% of my spinal surgery patients were compensation cases, which always delayed their return to work by more like 3 months. Using MacNab's criteria, patients classified as "good" could not be considered a surgical success in my publications and would require re-evaluation for their ongoing symptoms. My published definition of "surgical cure" for the same type of pathology treated over a 20-year period is "a patient who is economically productive if they so desire, physically comfortable without addictive pain medication, and free from sciatic pain." [1].

Microlumbar discectomy (MLD) was my attempt to treat the exact same surgical pathology as presented in Dr. Ditsworth's series. It represents a minimally invasive open surgical technique, the ongoing surgical results of which have often been reviewed over the years in the neurosurgical literature. This totally microsurgical technique has certainly stood the test of time [1]. Its major critics have always complained about the limitations of microsurgical exposure. I wonder how insecure these same individuals might feel when trying to utilize a small diameter transforaminal endoscope to resolve lateral recess nerve root compression. MLD, however, is a surgical treatment with rigid surgical parameters and patient criteria. Do not confuse MLD with the term "microdiscectomy," which is rampant in the surgical literature. The latter term has no surgical parameters or patient criteria, and only implies the use of a surgical microscope during any type of lumbar disc operation.

For me, the surgical microscope, with its varying degrees of magnification and excellent depth of field under binocular vision, provided the technical means and surgical mobility to treat any type of lateral recess pathology encountered at the time of initial surgery. Certainly, though percutaneous lumbar techniques may have their selective applications, they cannot offer such a technical advantage to either the surgeon, patient, or perhaps the health care system. I would hate to see "stair step" spinal surgery become accepted as state-of-the-art.

Robert W. Williams, M.D.
Neurosurgeon
Red Lodge, Montana

REFERENCE

1. Williams RW. Lumbar disc disease: microdiscectomy. *Neurosurg Clin North Am* 1993;4:101-8.

Ditsworth's superb technological approach effectively dispels most of my previous criticism of the numerous so-called minimally invasive procedures.

Access to the epidural space through the foramen and at least some ability to maneuver within the spinal canal satisfies the requirement of direct contact with most disk herniations that require surgery.

Objection to intradiscal procedures comes from my often-repeated observation that most symptomatic disc fragments—those with neural compression requiring surgery—erupt into the spinal canal through an annular opening smaller than their actual size, a mushroom-type effect [1]. This has been the case whether the fragments are "contained" within the posterior longitudinal ligament or not. So the illogical idea that reducing intradiscal contents and pressure by the destructive agent Chymopain or by percutaneous discectomy can have any effect on disc fragments in the spinal canal or foramen ignores this biomechanical phenomenon. Some patients get better after these intradiscal procedures not because of them, but despite them.

My opposition to lumbar microdiscectomy was that it totally failed in reaching fragments cephalad or caudad to the disc space, that it had a higher rate of dural tears and vascular injuries, and that the patients fared no better than those who had surgery by an experienced, skilled surgeon who may or may not have used magnification.

Dr. Ditsworth's procedure understandably requires a combined transannular and foraminal approach; his success rate for lateral and foraminal lesions is equal to that of open surgery, but not surprisingly, lower than that of open surgery for paramedian fragments. He appropriately warns about patients who have had prior surgery, inaccessible fragments, and calcified or osteophytic lesions that may be producing root compression.

If I have any criticism at all of his general approach, it would be to question the need for discography, the results of which can hardly be considered reliable. I must also continue to raise some doubts about a pure intradiscal procedure on over four hundred patients. In this paper he does not share the indications or results of these with us, and it is difficult to abandon my inherent skepticism about their necessity.

Charles A. Fager, M.D.
Department of Neurosurgery
Lahey Hitchcock Medical Center
Burlington, Massachusetts

REFERENCE

1. Fager CA. Atlas of spinal surgery. Philadelphia: Lea & Febiger, 1989.